



Contents lists available at ScienceDirect

## Clinical Microbiology and Infection

journal homepage: [www.clinicalmicrobiologyandinfection.com](http://www.clinicalmicrobiologyandinfection.com)

## Original article

## Adverse birth outcomes associated with Zika virus exposure during pregnancy in São José do Rio Preto, Brazil

M.L. Nogueira<sup>1,\*</sup>, N.R.R. Nery Júnior<sup>4</sup>, C.F. Estofoleto<sup>1</sup>, A.C. Bernardes Terzian<sup>1</sup>, G.F. Guimarães<sup>1</sup>, N. Zini<sup>1</sup>, R. Alves da Silva<sup>1</sup>, G.C. Dutra Silva<sup>1</sup>, L.C. Junqueira Franco<sup>1</sup>, P. Rahal<sup>2</sup>, C. Bittar<sup>2</sup>, B. Carneiro<sup>2</sup>, P.F.C. Vasconcelos<sup>5</sup>, D. Freitas Henriques<sup>5</sup>, D.M.U. Barbosa<sup>3</sup>, P. Lopes Rombola<sup>3</sup>, L. de Grande<sup>3</sup>, A.F. Negri Reis<sup>3</sup>, S.A. Palomares<sup>3</sup>, M. Wakai Catelan<sup>3</sup>, L.E.A.A. Cruz<sup>3</sup>, S.H. Necchi<sup>3</sup>, R.C.V. Mendonça<sup>3</sup>, I.N. Penha dos Santos<sup>3</sup>, S.B. Alavarse Caron<sup>3</sup>, F. Costa<sup>4,6,9</sup>, F.A. Bozza<sup>7</sup>, A. Soares de Souza<sup>1</sup>, C.C. Brandão de Mattos<sup>1</sup>, L.C. de Mattos<sup>1</sup>, N. Vasilakis<sup>8</sup>, A.H. Oliani<sup>1</sup>, D.C.M. Vaz Oliani<sup>1</sup>, A.I. Ko<sup>9</sup>

<sup>1</sup> São José do Rio Preto School of Medicine, São José do Rio Preto, São Paulo, Brazil<sup>2</sup> São Paulo State University, São José do Rio Preto, São Paulo, Brazil<sup>3</sup> Health Secretariat, São José do Rio Preto, São Paulo, Brazil<sup>4</sup> Gonçalo Moniz Institute, Oswaldo Cruz Foundation, Salvador, Bahia, Brazil<sup>5</sup> Evandro Chagas Institute, Ananindeua, Pará, Brazil<sup>6</sup> Federal University of Bahia, Salvador, Bahia, Brazil<sup>7</sup> Fundacao Oswaldo Cruz, Rio de Janeiro, Brazil<sup>8</sup> University of Texas Medical Branch (UTMB), Galveston, TX, USA<sup>9</sup> Yale School of Public Health, New Haven, CT, USA

## ARTICLE INFO

## Article history:

Received 15 October 2017

Received in revised form

29 October 2017

Accepted 2 November 2017

Available online xxx

Editor: L. Leibovici

## Keywords:

Adverse outcome

Arbovirus

Birth

Pregnancy

Zika virus

## ABSTRACT

**Objectives:** We aimed to report the first 54 cases of pregnant women infected by Zika virus (ZIKV) and their virologic and clinical outcomes, as well as their newborns' outcomes, in 2016, after the emergence of ZIKV in dengue-endemic areas of São Paulo, Brazil.

**Methods:** This descriptive study was performed from February to October 2016 on 54 quantitative real-time PCR ZIKV-positive pregnant women identified by the public health authority of São José do Rio Preto, São Paulo, Brazil. The women were followed and had clinical and epidemiologic data collected before and after birth. Adverse outcomes in newborns were analysed and reported. Urine or blood samples from newborns were collected to identify ZIKV infection by reverse transcription PCR (RT-PCR).

**Results:** A total of 216 acute Zika-suspected pregnant women were identified, and 54 had the diagnosis confirmed by RT-PCR. None of the 54 women miscarried. Among the 54 newborns, 15 exhibited adverse outcomes at birth. The highest number of ZIKV infections occurred during the second and third trimesters. No cases of microcephaly were reported, though a broad clinical spectrum of outcomes, including lenticulostriate vasculopathy, subependymal cysts, and auditory and ophthalmologic disorders, were identified. ZIKV RNA was detected in 18 of 51 newborns tested and in eight of 15 newborns with adverse outcomes.

**Conclusions:** Although other studies have associated many newborn outcomes to ZIKV infection during pregnancy, these same adverse outcomes were rare or nonexistent in this study. The clinical presentation the newborns we studied was mild compared to other reports, suggesting that there is significant heterogeneity in congenital Zika infection. **M.L. Nogueira, Clin Microbiol Infect 2018;•:1**

© 2017 European Society of Clinical Microbiology and Infectious Diseases. Published by Elsevier Ltd. All rights reserved.

\* Corresponding author. M. L. Nogueira, São José do Rio Preto School of Medicine (FAMERP), 5416 Brigadeiro Faria Lima Ave, Vila São Pedro, São José do Rio Preto, São Paulo, 15090-000, Brazil.

E-mail address: [mnogueira@famerp.br](mailto:mnogueira@famerp.br) (M.L. Nogueira).

<https://doi.org/10.1016/j.cmi.2017.11.004>

1198-743X/© 2017 European Society of Clinical Microbiology and Infectious Diseases. Published by Elsevier Ltd. All rights reserved.

## Introduction

Zika virus (ZIKV) infection has been associated with severe birth defects, such as newborn microcephaly [1,2], meningoencephalitis [3] and Guillain-Barré syndrome (<http://ecdc.europa.eu/en/publications/Publications/zika-virus-america-association-with-microcephaly-rapid-risk-assessment.pdf>) [4]. Microcephaly represents a small part of a broad spectrum of teratogenic outcomes of intrauterine ZIKV infection referred to as congenital Zika syndrome [5]. Intrauterine growth restriction, ocular abnormalities, placental damage, foetal blood anomalies [6] and death are other findings that may be associated with ZIKV infection during pregnancy [1,2,7].

The city of São José do Rio Preto in São Paulo State, Brazil, is a region in which several arbovirus circulate [8–10]. In 2016 a ZIKV outbreak was reported in the city [11], and a surveillance system was established to identify illnesses caused by ZIKV. Special attention has been paid to pregnant women in an attempt to ascertain the impact of ZIKV infection on newborns. This study is a report of the first 54 confirmed cases of women infected by ZIKV during pregnancy and their virologic and clinical outcomes, as well as their newborns' outcomes, identified through our surveillance system.

## Methods

### Study population

From February to October 2016, the city's public health authority identified 216 pregnant patients with Zika-like symptoms among 1674 pregnant women receiving elective and emergency services. The Brazilian Ministry of Health defines Zika-suspected cases on the basis of macular or papular rash with two or more of the following signs or symptoms: fever, conjunctival hyperaemia without secretion, pruritus, polyarthralgia or joint oedema [12]. Fifty-seven pregnant women with symptomatic acute Zika-suspected infection between 5 and 38 weeks of pregnancy (gestational age defined as first trimester until week 13, second trimester from weeks 14 to 26, and third trimester after week 27) [13] who attended a health service in São José do Rio Preto were considered to be Zika-suspected patients and had a blood sample collected during acute infection which was found to be ZIKV RT-PCR positive. These pregnant women were referred to the Children's and Maternity Hospital in São José do Rio Preto, São Paulo, Brazil, the reference hospital, and were monitored under a protocol approved by the São José do Rio Preto medical school institutional review board. These blood samples were also tested for toxoplasmosis, other agents (including HIV, when relevant), rubella, cytomegalovirus, herpes simplex, and syphilis (TORCHS) using molecular and/or serologic methods. The ZIKV-positive pregnant women were monitored by a multidisciplinary medical team through the use of clinical and radiologic evaluations.

After delivery, the newborn's umbilical cord blood and/or urine were collected and tested for the presence of ZIKV by molecular and serologic methods. The clinical examinations of newborn and anthropometric measurements were performed according to the guidelines of the Brazilian Ministry of Health [12], including definition of microcephaly, as newborns of 37 weeks' gestation or less and cephalic perimeter lower than 2 standard deviations (based on INTERGROWTH-21st Project data) for gestational age and sex [14]; or newborns of 37 weeks' gestation or more and cephalic perimeter of less than or equal to 31.5 cm for girls and 31.9 cm for boys, and equivalent to lower than 2 standard deviations (based on World Health Organization criteria) [15]. The following were considered to be adverse outcomes: lenticulostriate vasculopathy, subependymal cysts, choroidal cyst, bilateral cranial bleed,

chorioretinitis, premature birth and abnormal otoacoustic emission (OAE).

Ultrasounds were performed with an HDI 5000 convex probe (Philips, Amsterdam, The Netherlands) in order to generate foetal and postnatal images. Magnetic resonance imaging was performed with a Philips Gyroscan Intera 1.5 T scanner, and the images were analysed by specialists in foetal medicine. Special attention was given to the foetus's or newborn's central nervous system. When available, OAE tests and fundus examinations were performed by specialists to identify any auditory or ophthalmologic disorders, respectively.

### Virus and RNA extraction

The virus strain used as positive control was ZIKV<sup>BR</sup>. It was propagated in C6/36 *Aedes albopictus* cell cultures [15–17]. Virus RNA was extracted from 140 µL blood and urine samples with the QIAamp Viral RNA Mini kit (Qiagen, Germantown, MD, USA) according to the manufacturer's instructions.

### ZIKV quantitative real-time PCR

To detect the ZIKV genome in mothers' blood or newborns' umbilical cord blood and/or urine samples, a one-step quantitative real-time, fluorescent probe-based RT-PCR (qPCR) assay was performed using primers targeting the envelop (E) gene [18]. All samples with  $C_t$  values of 38.5 or less were considered positive for ZIKV.

### ZIKV ELISA

The umbilical cord blood samples found to be positive for ZIKV in qPCR were also tested for the Zika NS1 protein. The Zika Virus NS1 ELISA Kit (BioFront Technologies, Tallahassee, FL, USA) was used to capture anti-ZIKV NS1. All of the assays were performed according to the manufacturer's instructions. Each plate was read at 450 nm using a Spectramax Plus Microplate reader (Molecular Devices, Sunnyvale, CA, USA).

### Complete genome

After RNA extraction, cDNA was synthesized using the High Capacity cDNA Reverse Transcription kit (Applied Biosystems; Thermo Fisher Scientific, Waltham, MA, USA). Nineteen fragments were amplified by nested PCR using Phusion high-fidelity DNA polymerase (Thermo Fisher Scientific). Fragment sizes ranged from 430 to 1461 bp. Nested PCR products were purified using the DNA Clean & Concentrator Kit (Zymo Research, Irvine, CA, USA). Fragments were sequenced using the direct Sanger method with BigDye Terminator 3.1 in an ABI 3130XL Genetic Analyzer (Applied Biosystems). Sequences were assembled and analysed for coverage and quality by SeqMan software from the Lasergene package (DNASTAR, Madison, WI, USA).

### Phylogenetic reconstruction

The evolutionary history was inferred using the maximum likelihood method based on the general time reversible model [19] using a data set compiled of 99 complete open reading frame nucleotide sequences available in GenBank. The tree with the highest log likelihood (−35779.2777) is shown in [Supplementary Fig. S1](#). The percentage of trees in which the associated taxa clustered together is shown next to the branches. Initial trees for the heuristic search were obtained automatically by applying the Neighbor-Join and BioNJ algorithms to a matrix of pairwise

distances estimated using the maximum composite likelihood approach and then selecting the topology with superior log likelihood value. A discrete gamma distribution was used to model differences in evolutionary rates among sites (five categories; +G, parameter = 0.2918). The rate variation model allowed for some sites to be evolutionarily invariable ([+I], 0.0010% sites). The tree is drawn to scale, with branch lengths measured in the number of substitutions per site. Codon positions included were

1 + 2 + 3 + noncoding. All positions containing gaps and missing data were eliminated. There were a total of 10,208 positions in the final data set. Evolutionary analyses were conducted in MEGA7 [20].

### Statistical analysis

All statistical analyses were carried out using the Epi Info software for Windows (Centers for Disease Control and Prevention,

**Table 1**  
Characteristics of women in cohort and their pregnancies according to infants' birth outcomes

Characteristic	Total (n = 54)			Adverse birth outcomes <sup>a</sup> (n = 15)			No adverse birth outcomes (n = 39)			p
	No. of responses	No. of positives or median	(% or IQR)	No. of responses	No. of positives or median	(% or IQR)	No. of responses	No. of positives or median	(% or IQR)	
<b>Demographic data</b>										
Mother's age (years)	54	27.5	(23–34)	15	23	(21–38)	39	28	(22–34)	0.68
Ethnicity										
White	45	31	(69)	14	9	(64)	31	22	(71)	0.83
Mestizo	45	10	(22)	14	4	(29)	31	6	(19)	—
Black	45	3	(7)	14	1	(7)	31	2	(6)	—
Other	45	1	(2)	14	0	(0)	31	1	(3)	—
Educational level completed										
College education	44	10	(23)	14	2	(14)	30	8	(27)	0.51
High school	44	26	(59)	14	10	(71)	30	16	(53)	—
Primary school	44	8	(18)	14	2	(14)	30	6	(20)	—
Medical history										
Paras	37	1	(0–2)	12	1	(0.5–2)	25	1	(0–1)	0.60
Gravidas	37	2	(1.5–3.5)	12	2	(1.5–3)	25	2	(2.5–3)	0.80
Comorbidities <sup>b</sup>	54	9	(17)	15	3	(20)	39	6	(15)	0.68
STD	45	4	(9)	14	2	(14)	31	2	(6)	0.39
<b>Zika infection during pregnancy</b>										
Trimester of ZIKV infection										
First trimester	54	4	(7)	15	1	(7)	39	3	(8)	0.20
Second trimester	54	26	(48)	15	4	(27)	39	22	(56)	—
Third trimester	54	24	(44)	15	10	(67)	39	14	(36)	—
Rash	53	51	(96)	15	14	(93)	39	37	(95)	0.49
Pruritus	54	34	(63)	15	10	(67)	39	24	(62)	0.73
Headache	54	23	(43)	15	5	(33)	39	18	(46)	0.39
Arthralgias	54	21	(39)	15	7	(47)	39	14	(36)	0.47
Fever	54	18	(33)	15	3	(20)	39	15	(38)	0.20
Myalgias	54	15	(28)	15	4	(27)	39	11	(28)	0.91
Respiratory symptoms <sup>c</sup>	54	8	(15)	15	0	(0)	39	8	(20)	0.06
Conjunctivitis	54	1	(2)	15	0	(0)	39	1	(3)	0.53
Serum ZIKV RT-PCR positive	53	45	(85)	15	14	(93)	38	31	(82)	0.28
Urine ZIKV RT-PCR positive	52	41	(79)	14	10	(71)	38	31	(82)	0.43
Pregnancy										
Current alcohol drinker	44	2	(5)	14	1	(7)	30	1	(3)	0.57
Current smoker	44	6	(14)	14	2	(14)	30	4	(13)	0.93
Medications <sup>d</sup>	54	35	(65)	15	10	(67)	39	25	(64)	0.86
Complications <sup>e</sup>	44	10	(23)	14	4	(29)	30	6	(20)	0.53
TORCH serology										
Toxoplasmosis IgM positive	47	2	(4)	13	1	(8)	34	1	(3)	0.47
CMV IgM positive	47	0	(0)	13	0	(0)	34	0	(0)	NA
Rubella IgM positive	47	4	(9)	13	0	(0)	34	4	(12)	0.20
VDRL positive	49	1	(2)	13	1	(8)	36	0	(0)	0.09
US/MRI exam										
No. of prenatal US exams	51	3	(3–3)	14	3	(3–3)	37	3	(3–3)	0.80
Abnormal prenatal US exam <sup>f</sup>	51	2	(4)	14	2	(14)	37	0	(0)	0.02
Abnormal foetal MRI <sup>g</sup>	25	6	(24)	8	1	(13)	17	5	(29)	0.36

CMV, cytomegalovirus; IQR, interquartile range; MRI, magnetic resonance imaging; NA, not applicable; RT-PCR, reverse transcription PCR; STD, sexually transmitted disease; TORCH, toxoplasmosis, other agents (including HIV, when relevant), rubella, cytomegalovirus, herpes simplex; US, ultrasound; VDRL, Venereal Disease Research Laboratory test; ZIKV, Zika virus.

<sup>a</sup> Adverse outcomes: lenticulostriate vasculopathy, subependymal cysts, choroidal cyst, bilateral cranial bleed, chorioretinitis, premature birth, abnormal otoacoustic examination.

<sup>b</sup> Comorbidities: with adverse outcomes: hypothyroidism (1), idiopathic thrombocytopenic purpura (1), chronic cardiopathy (1), hypertension (1); with no adverse outcomes: hypothyroidism (2), hypertension (3).

<sup>c</sup> Coryza, sore throat or cough.

<sup>d</sup> Medications: with adverse outcomes: levothyroxine (1), prednisone (1), methylodopa (1), sulfadiazine plus pyrimethamine (1), acyclovir (1); with no adverse outcomes: levothyroxine (1), methylodopa (2), methylodopa plus metformin (1), levothyroxine plus metformin (1), clindamycin (1), spiramycin (1).

<sup>e</sup> Complications during pregnancy: with adverse outcomes: gestational diabetes (1), herpes simplex virus infection (1), syphilis (1), acute toxoplasmosis (1); with no adverse outcomes: gestational diabetes (2), rubella (4); acute toxoplasmosis (1).

<sup>f</sup> US: with adverse outcomes: retro-ovulate haematoma (1), oligohydramnios (1).

<sup>g</sup> MRI (no significant findings): with adverse outcomes: eccentric placental insertion of umbilical cord (1); with no adverse outcomes: placental thickening (1), asymmetrical thyroid lobes (1), increased subtentorial measures plus pericardial effusions (1), right renal cyst in foetus (1), swallowing failure and gastric distention (1).

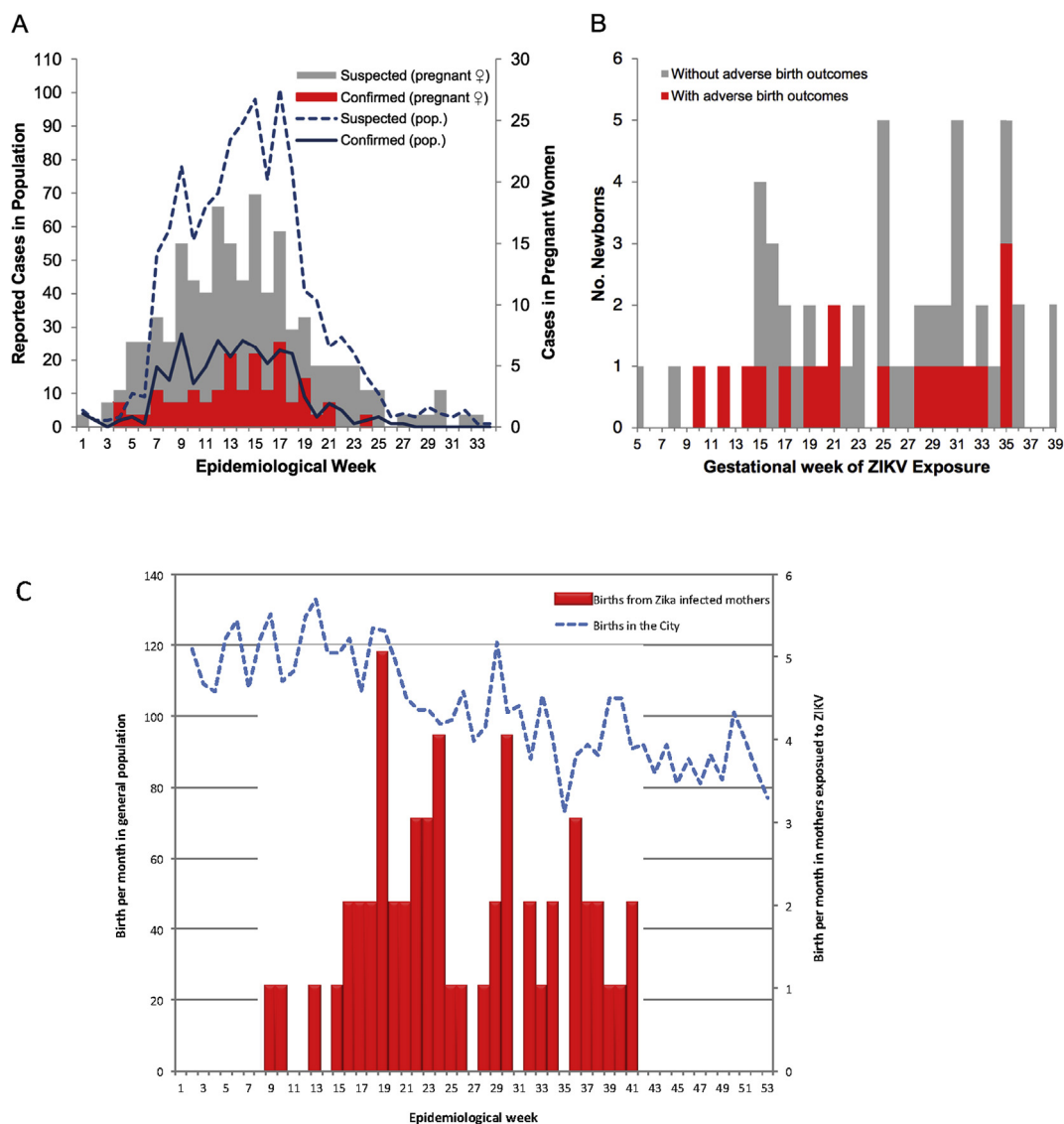
Atlanta, GA, USA). We used chi-square and Wilcoxon rank sum tests to compare the characteristics according to birth outcomes for categorical and continuous data, respectively.

## Results

Among 216 symptomatic acute ZIKV-suspected pregnant women in the São José do Rio Preto public health system between February 2016 and October 2016, this descriptive study included 57 pregnant women (26%) who had ZIKV infection confirmed by RT-PCR in blood. Three pregnant women (5%) were lost to follow-up, resulting in a final sample size of 54 women. ZIKV infection was detected in all trimesters of gestation. Fifteen pregnant women (28%) experienced adverse birth outcomes. The clinical and demographic characteristics of the 54 mothers and their respective newborns are shown in Table 1. The distribution of suspected and confirmed cases of ZIKV according to epidemiologic week and gestational week of ZIKV exposure as well as the associations between these data and adverse outcomes are shown in Figs 1 and 2.

No pregnant woman in this study miscarried, and only eight (15%) of the foetuses were born at less than 37 weeks' gestation. The Apgar score median of the newborns was 9 of 10 and 10 of 10 at 1 and 5 minutes, respectively; two newborns had Apgar scores lower than 7 at 1 minute and none at 5 minutes, and no abnormalities were detected in the neurologic examinations. The additional serologic screening performed for infectious diseases during pregnancy is shown in Table 1 and Supplementary Table S4. Findings of radiologic examinations are shown in Tables 1 and 2.

Almost a quarter of pregnant women (28%, 15/54) who received follow-up care presented adverse foetal/birth outcomes (Supplementary Table S1). In three cases (20%) there were histories of comorbidities, and in seven cases the mother reported exposure to alcohol, tobacco or illicit drugs (Table 1 and Supplementary Table S1). One newborn, born prematurely, encountered all of the anthropometric parameters below those expected for gestational age, compatible with intrauterine growth restriction. In this same newborn, unilateral ultrasound, abnormal OAE test results and ZIKV in cord blood (RT-PCR) were all identified, without other



**Fig. 1.** Suspected and confirmed cases of Zika virus (ZIKV) infection according to epidemiologic week (panel A), gestational week of ZIKV exposure (panel B) and birth rate of ZIKV-infected pregnant women (panel C) in São José do Rio Preto, São Paulo, Brazil, in 2016.

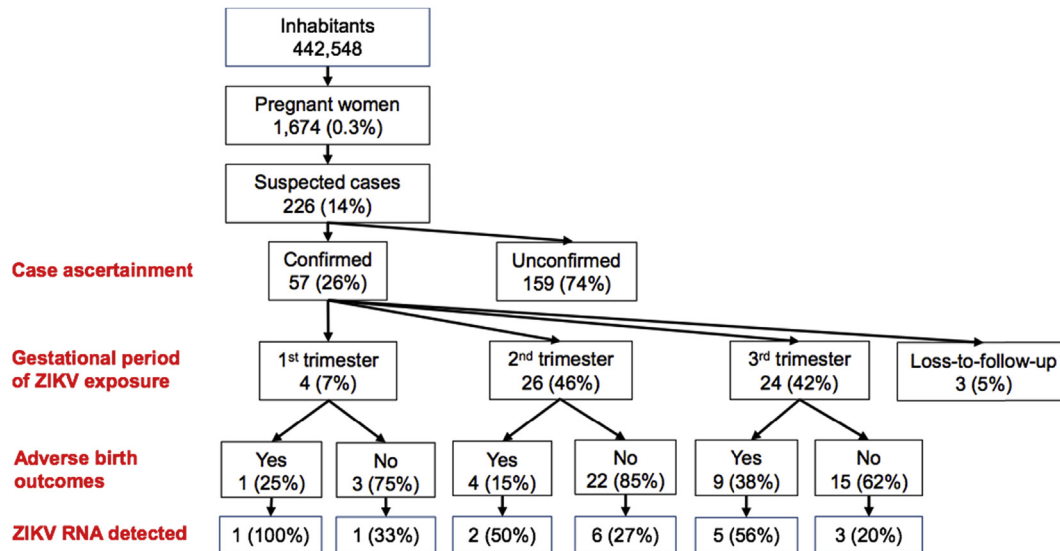


Fig. 2. Characteristics of maternal cohort, Zika infection and adverse outcomes in São José do Rio Preto, São Paulo, Brazil, in 2016.

infectious agents but with exposure to illicit drugs (marijuana) during gestation. The adverse outcomes observed in each case of ZIKV exposure *in utero* are listed in [Supplementary Tables S1–S3](#).

Among the 39 newborns with no adverse birth outcomes, the profile of ZIKV exposure was similar to those with adverse outcomes. Clinical and laboratory data of these newborns are presented in [Table 2](#). The serologic and molecular tests for ZIKV are shown in [Supplementary Table S6](#).

Evidence of ZIKV infection was detected in 18 (35%) of 51 newborns who were evaluated by RT-PCR at birth using umbilical cord blood and/or urine samples ([Table 3](#)). Among the newborns who did not exhibit adverse outcomes, ZIKV RNA was detected in ten (28%) of 36 ([Supplementary Tables S4–7](#)). The complete genome of ZIKV was amplified from one patient and two controls, all adult men, and sequenced. Phylogenetic analyses revealed that the ZIKV identified in our mothers during the 2016 outbreak was clustered together with the same virus circulating in other areas of the country ([Supplementary Fig. S1](#)).

## Discussion

On the basis of surveillance alerts, our health centre has been conducting a prospective study on ZIKV in pregnancy and associated birth defects (with a focus on microcephaly) since January 2016. In ten months of surveillance, there were 216 cases of ZIKV-suspected pregnant women in our centre, and here we report 54 cases (26%) of pregnant women who were found to have ZIKV infection confirmed by RT-PCR in blood samples. Fifteen adverse foetal/birth outcomes and 18 cases of congenital ZIKV infection in newborns were reported. Although ZIKV infection in the first trimester of gestation is associated with microcephaly [1,2], no such cases have been detected thus far among the newborns in our cohort. Most of the adverse neurologic outcomes (14/15, 94%) occurred in the second and third trimesters, and this may have been responsible for these mild outcomes.

This is not the first report to associate ZIKV infection after the first trimester with regular head circumference at birth but with adverse clinical outcomes, such as congenital brain injury acquired as a result of ZIKV [21]. The outcomes associated with ZIKV infection during pregnancy may include no effects, miscarriage or foetal

infection resulting in congenital Zika syndrome [22]. An important study performed in Brazil in 2016 [1] reported several outcomes in fetuses and newborns exposed to ZIKV during pregnancy, as intrauterine growth restriction, cerebral calcifications, abnormal arterial flow in the cerebral or umbilical arteries, global cerebral atrophy, microcephaly, macular hypoplasia and scarring, and placental insufficiency.

Congenital anomalies, including microcephaly, have a complex and multifactorial aetiology and may be caused by other infections (such as TORCH infections) during pregnancy, as well as chromosomal disorders, exposure to environmental toxins and metabolic diseases [22,23]. Congenital toxoplasmosis [24], syphilis [25], herpes simplex virus [26] and rubella [27,28] may affect the central nervous system and cause neurologic deficits. Out of all of the cases in this study in which subependymal cysts were observed, only one pregnant woman had a reagent toxoplasmosis IgM result and a newborn who was ZIKV RT-PCR positive in the umbilical cord blood. Among those with vasculopathy, the only infection identified was that of ZIKV. These factors lead us to believe that ZIKV can be the cause of neurologic abnormalities. Knowing the cause of these issues is an important tool for prevention.

Because this is a descriptive study, a control group of women with no infection was not defined. A limitation presented by this study was the lack of data in some variables. The data were collected by the attending physician on the basis of a preestablished record, although it was not always completely filled out. The clinical spectrum observed in our newborns differed from those reported in other studies. Lenticulostriate vasculopathy, subependymal cysts, auditory disorder and chorioretinitis were the main outcomes observed, and there were no cases of macular hypoplasia, microcephaly or abnormal neurologic test results after birth. These findings showed that the symptoms of congenital Zika syndrome might be broader than originally thought. The link to ZIKV may not be clearly established nor excluded. In some cases, the only infectious agent detected was ZIKV. In cases where other infectious agents were identified by serologic tests, the clinical findings were not usually related to them.

In conclusion, our study highlights the importance of ZIKV infection in all trimesters of gestation. Brain abnormalities other than microcephaly, intracerebral calcifications or severe outcomes

**Table 2**  
Characteristics of newborn infants according to birth outcome

Characteristic	Total (n = 54)			Adverse birth outcomes (n = 15)			No adverse birth outcomes (n = 39)			p
	No. of responses	No. of positives or median	(% or IQR)	No. of responses	No. of positives (% or IQR)	No. of responses	No. of positives (% or IQR)	No. of positives (% or IQR)		
<b>Birth</b>										
Gestational age at birth (weeks)	54	38	(37.5–38)	15	38	(37–39)	39	38	(37–38.5)	0.83
Premature (<37 weeks' gestation)	54	8	(15)	15	3	(20)	39	5	(13)	0.51
Male sex	54	30	(56)	15	6	(40)	39	24	(62)	0.15
Caesarean section delivery	35	29	(83)	12	11	(92)	23	18	(78)	0.32
Apgar score (median)										
At 1 minute	33	9	(9–9)	11	9	(9–9)	22	9	(9–9)	0.30
At 5 minutes	33	10	(9–10)	11	10	(10–10)	22	10	(9.5–10)	0.09
<b>Anthropometric measurements</b>										
Head circumference										
Circumference (cm)	53	35	(34–36)	15	35	(34–36)	39	35	(34–36)	0.71
Percentile <sup>a</sup>	53	89	(77–97)	15	92	(76–98)	39	89	(79–96)	0.78
Microcephaly <sup>b</sup>	54	0	(0)	15	0	(0)	39	0	(0)	—
Weight										
Weight (g)	54	3097	(2901–3420)	15	2970	(2894–3486)	39	3098	(2929–3460)	0.62
Percentile <sup>b</sup>	54	66	(39–82)	15	65	(44–85)	39	66	(39–84)	0.95
Small for gestational age <sup>b</sup>	54	0	(0)	15	0	(0)	39	0	(0)	—
Length										
Length (cm)	54	48	(46.8–49.5)	15	47	(46–48)	39	48	(47–49)	0.05
Percentile	54	43	(27–71)	15	32	(14–56)	39	48	(34–73)	0.05
<b>Clinical evaluation</b>										
Abnormal neurologic evaluation	54	0	(0)	14	0	(0)	40	0	(0)	NA
Abnormal ophthalmologic exam <sup>c</sup>	22	2	(9)	10	2	(20)	12	0	(0)	0.10
Abnormal OAE/AABR <sup>d</sup>	34	6	(18)	14	6	(43)	20	0	(0)	0.00
Radiologic evaluations										
Cranial US <sup>e</sup>	38	7	(18)	14	7	(50)	24	0	(0)	0.00
Cranial MRI	3	0	(0)	1	0	(0)	2	0	(0)	NA
<b>ZIKV diagnostic testing</b>										
RT-PCR positive	51	18	(35)	15	8	(53)	36	10	(28)	0.08
Serum	48	14	(29)	15	5	(33)	33	9	(27)	0.67
Serum C <sub>t</sub>	14	36.5	(36–37)	5	36.3	(36.2–36.5)	9	36.8	(35.6–37.4)	0.31
Urine	46	4	(9)	15	3	(20)	31	1	(3)	0.06
Urine C <sub>t</sub>	4	36.5	(31–36.6)	3	36.4	(31–36.6)	1	37.7	—	0.18
Trimester of infection										
First trimester	18	2	(11)	8	1	(13)	10	1	(10)	0.20
Second trimester	18	8	(44)	8	2	(25)	10	6	(60)	—
Third trimester	18	8	(44)	8	5	(63)	10	3	(30)	—
MAC-ELISA positive ZIKV	16	0	(0)	7	0	(0)	9	0	(0)	NA
Hospitalization										
Days	37	2	(2–4)	14	2	(2–4)	23	2	(2.5–4.5)	0.64
NICU admission	54	5	(9)	15	0	(0)	39	5	(13)	0.15

AABR, automated auditory brain stem response; MAC-ELISA, dengue IgM capture enzyme-linked immunosorbent assay; MRI, magnetic resonance imaging; NA, not applicable; OAE, otoacoustic examination; RT-PCR, reverse transcription PCR; US, ultrasound; ZIKV, Zika virus.

<sup>a</sup> Value less than –2 standard deviations head circumference.

<sup>b</sup> Value <10th weight percentile.

<sup>c</sup> Abnormal ophthalmologic exam: unilateral chorioretinitis.

<sup>d</sup> OAE: one case, confirmed by AABR.

<sup>e</sup> US: with adverse outcomes: lenticulostriate vasculopathy (2), subependymal cysts (3), choroidal cyst (1), bilateral cranial bleed (1).

**Table 3**  
Outcomes among newborns from mothers exposed to ZIKV during pregnancy

Outcome	No. of cases	Incidence (95% CI)
Adverse birth outcome	15/54	28 (17–41)
Exposure in first trimester	1/4	25 (0.63–81)
Exposure in second trimester	4/26	15 (5–33)
Exposure in third trimester	10/24	42 (23–62)
ZIKV detected at birth	8/18	44 (23–67)
ZIKV not detected at birth	7/15	47 (23–71)
ZIKV detection at birth	18/51	35 (22–48)
ZIKV exposure in first trimester	2/4	50 (9–91)
ZIKV exposure in second trimester	8/26	31 (15–50)
ZIKV exposure in third trimester	8/24	33 (14–52)
With adverse outcomes	8/15	53 (29–77)
No adverse outcomes	10/39	26 (14–41)

Cumulative incidence shown as cases per 100 births.  
CI, confidence interval; ZIKV, Zika virus.

detected by imaging examinations during pregnancy may occur, reflecting the marked heterogeneity of exposure to ZIKV during pregnancy. Adverse outcomes were mild or nonexistent in our newborns, but their occurrence may affect neurologic development, thus having an important negative impact on the patient specifically and on the population more generally. These impacts may only be measured some years after birth. This study provides additional evidence of the association between congenital ZIKV infection and certain foetal outcomes, and it contributes to a better understanding in the pathogenesis of birth defects caused by ZIKV.

#### Transparency declaration

Supported by the São Paulo Research Foundation (FAPESP) via grants 2013/21719-3 and 2016/15021-1 to MLN, grant 2015/12295-0

to ACBT and grant 2016/05115-9 to LCM. The opinions, assumptions and conclusions or recommendations expressed in this material are the responsibility of the authors and do not necessarily reflect the views of FAPESP. PFCV was supported by the Zika Virus Fast Track program provided by the Coordination for the Improvement of Higher Level Education Personnel and the Brazilian National Council for Scientific and Technological Development (CNPq) by grants 303999/2016-0, 440405/2016-5 and 457664/2013-4. MLM is a CNPq research fellow. All authors report no conflicts of interest relevant to this article.

#### Appendix A. Supplementary data

Supplementary data related to this article can be found at <https://doi.org/10.1016/j.cmi.2017.11.004>.

#### References

- [1] Brasil P, Pereira JP, Moreira ME, Ribeiro Nogueira RM, Damasceno L, Wakimoto M, et al. Zika virus infection in pregnant women in Rio de Janeiro. *N Engl J Med* 2016;375:2321–34.
- [2] Mlakar J, Korva M, Tul N, Popovic M, Poljsak-Prijatelj M, Mraz J, et al. Zika virus associated with microcephaly. *N Engl J Med* 2016;374:951–8.
- [3] Carteaux G, Maquart M, Bedet A, Contou D, Brugieres P, Fourati S, et al. Zika virus associated with meningoencephalitis. *N Engl J Med* 2016;374:1595–6.
- [4] Baud D, Gubler DJ, Schaub B, Lanteri MC, Musso D. An update on Zika virus infection. *Lancet* 2017;4:2009–109.
- [5] Moore CA, Staples JE, Dobyms WB, Pessoa A, Ventura CV, Fonseca EB, et al. Characterizing the pattern of anomalies in congenital Zika syndrome for pediatric clinicians. *JAMA Pediatr* 2017;171:288–95.
- [6] Schaub B, Vouga M, Najioullah F, Gueneret M, Monthieux A, Harte C, et al. Analysis of blood from Zika virus-infected fetuses: a prospective case series. *Lancet Infect Dis* 2017;17:520–7.
- [7] Petersen LR, Jamieson DJ, Powers AM, Honein MA. Zika virus. *N Engl J Med* 2016;374:1552–63.
- [8] Mondini A, Chiaravalloti Neto F, Gallo y Sanches M, Lopes JC. Spatial analysis of dengue transmission in a medium-sized city in Brazil. *Rev Saude Publica* 2005;39:444–51.
- [9] Mondini A, Bronzoni RV, Cardeal IL, dos Santos TM, Lazaro E, Nunes SH, et al. Simultaneous infection by DENV-3 and SLEV in Brazil. *J Clin Virol* 2007;40:84–6.
- [10] Terzian AC, Mondini A, Bronzoni RV, Drummond BP, Ferro BP, Cabrera EM, et al. Detection of Saint Louis encephalitis virus in dengue-suspected cases during a dengue 3 outbreak. *Vector Borne Zoonotic Dis* 2011;11:291–300.
- [11] Fernanda Estofolete C, Terzian AC, Parreira R, Esteves A, Hardman L, Greque GV, et al. Clinical and laboratory profile of Zika virus infection in dengue suspected patients: a case series. *J Clin Virol* 2016;81:25–30.
- [12] Nota informativa—SVS/MS. Procedimentos a serem adotados para a vigilância da Febre do vírus Zika no Brasil. Brasília: Ministerio da Saude; 2016.
- [13] Assistência Pre-natal: manual tecnico. 3rd ed. Brasília: Secretaria de Políticas de Saude; 2000. p. 66.
- [14] Villar J, Cheikh Ismail L, Victora CG, Ohuma EO, Bertino E, Altman DG, et al. International standards for newborn weight, length, and head circumference by gestational age and sex: the Newborn Cross-Sectional Study of the INTERGROWTH-21st Project. *Lancet* 2014;384:857–68.
- [15] World Health Organization. Assessment of infants with microcephaly in the context of Zika virus. Geneva: World Health Organization; 2016. p. 2.
- [16] Shope RE, Sather GE. Arboviruses. In: Lennet FH, Schmidt NJ, editors. Diagnostic procedures for viral, rickettsial and clamydial infections. 2nd ed. Washington, DC: American Public Health Association; 1979. p. 767–814.
- [17] Figueiredo LT. The use of *Aedes albopictus* C6/36 cells in the propagation and classification of arbovirus of the *Togaviridae*, *Flaviviridae*, *Bunyaviridae* and *Rhabdoviridae* families. *Rev Soc Bras Med Trop* 1990;23:13–8.
- [18] Lanciotti RS, Kosoy OL, Laven JJ, Velez JO, Lambert AJ, Johnson AJ, et al. Genetic and serologic properties of Zika virus associated with an epidemic, Yap State, Micronesia, 2007. *Emerg Infect Dis* 2008;14:1232–9.
- [19] Nei M, Kumar S. Molecular evolution and phylogenetics. In: New ed. New York: Oxford University Press; 2000. p. 333 il.
- [20] Kumar S, Stecher G, Tamura K. MEGA7: molecular evolutionary genetics analysis version 7.0 for bigger datasets. *Mol Biol Evol* 2016;33:1870–4.
- [21] Soares de Souza A, Moraes Dias C, Braga FD, Terzian AC, Estofolete CF, Oliani AH, et al. Fetal infection by Zika virus in the third trimester: report of 2 cases. *Clin Infect Dis* 2016;63:1622–5.
- [22] Silasi M, Cardenas I, Kwon JY, Racicot K, Aldo P, Mor G. Viral infections during pregnancy. *Am J Reprod Immunol* 2015;73:199–213.
- [23] Kleber de Oliveira W, Cortez-Escalante J, De Oliveira WT, do Carmo GM, Henriques CM, Coelho GE, et al. Increase in reported prevalence of microcephaly in infants born to women living in areas with confirmed Zika virus transmission during the first trimester of pregnancy—Brazil, 2015. *MMWR Morb Mortal Wkly Rep* 2016;65:242–7.
- [24] Singh S. Congenital toxoplasmosis: clinical features, outcomes, treatment, and prevention. *Trop Parasitol* 2016;6:113–22.
- [25] Centers for Disease Control and Prevention. Sexually transmitted diseases treatment guidelines, 2015. *MMWR Recomm Rep* 2015;64:138.
- [26] Enright AM, Prober CG. Neonatal herpes infection: diagnosis, treatment and prevention. *Semin Neonatol* 2002;7:283–91.
- [27] Rorke LB. Nervous system lesions in the congenital rubella syndrome. *Arch Otolaryngol* 1973;98:249–51.
- [28] Miller E, Craddock-Watson JE, Pollock TM. Consequences of confirmed maternal rubella at successive stages of pregnancy. *Lancet* 1982;2:781–4.